











Monkeypox in Liver Transplant Patient

Tércio Genzini^{1*} , Thais Natália de Almeida¹ , Marina Guitton Rodrigues¹ , Sabrina Rodrigues de Figueiredo¹ ,
Maira Andrade Nacimbem Marzinotto¹ , Luís Edmundo Pinto da Fonseca¹ , Raquel Silveira Bello Stucchi¹ ,
Tomas Navarro Rodriguez¹ , Regina Gomes dos Santos¹ , Marcelo Perosa¹ 

1. Hospital Alemão Oswaldo Cruz [ROR] – Unidade Vergueiro – São Paulo/SP – Brazil.

*Corresponding author: tgenzini@hotmail.com

Section editor: Ilka de Fátima Santana F Boin 

Received: Apr. 11, 2023 | Accepted: May 22, 2023

How to cite: Genzini T, Almeida TN, Rodrigues MG, Figueiredo SR, Marzinotto MAN, Fonseca LEP, Stucchi RSB, Rodriguez TN, Santos RG, Perosa M. Monkeypox in Liver Transplant Patient. BJT. 2023.26 (01): e2023. https://doi.org/10.53855/bjt.v26i1.510_ENG

ABSTRACT

Monkeypox (MKP) is a zoonosis caused by a DNA virus belonging to the *Orthopoxvirus* genus in the *Poxviridae* family and was isolated for the first time in Denmark, in 1958. In 1970, the first case in humans was described in the Democratic Republic of Congo and, since then, it has spread with inter-human dissemination and, in July 2022, the WHO declared a state of health emergency. Its clinical presentation is similar to that of smallpox, with skin eruptions that evolve as macules, papules, vesicles, pustules and crusts. The first case in a transplanted patient was described in Thailand, in June 2022, in a bone marrow transplanted patient. In this report, we describe the case of MKP in a patient in the postoperative period of liver transplantation. We also discuss clinical aspects of this situation, which is still little known among the transplant community.

Descriptors: Monkeypox; Liver transplantation; Postoperative.

Monkeypox em paciente transplantado hepático

RESUMO

Monkeypox (MKP) é uma zoonose causada por um vírus DNA pertencente ao gênero *Orthopoxvirus* e à família *Poxviridae* e foi isolado pela primeira vez na Dinamarca em 1958. Em 1970 descreveu-se o primeiro caso em humanos, na República Democrática do Congo e desde então propagou-se com disseminação inter-humana e em julho de 2022 a OMS declarou estado de emergência sanitária. Sua apresentação clínica é semelhante à da varíola, com erupções cutâneas que evoluem como máculas, pápulas, vesículas, pústulas e crostas. O primeiro caso em transplantado foi descrito na Tailândia em junho de 2022, num paciente transplantado de medula. Nesse relato, descrevemos caso de MKP num paciente em pós-operatório de transplante de fígado e discutimos aspectos clínicos nessa situação ainda pouco conhecida entre os transplantadores.

Descritores: Monkeypox; Transplante de Fígado; Pós-operatório.

INTRODUCTION

Monkeypox (MKP) is a zoonosis caused by a DNA virus belonging to the *Orthopoxvirus* genus in the *Poxviridae* family. The virus was first isolated in 1958 in research monkeys in Denmark. The first confirmed case in humans occurred in 1970 in the Democratic Republic of Congo (DRC) and was related to living with wild animals¹⁻³. Since then, MKP has become endemic in the DRC and has spread to other African countries, also with inter-human spread.⁴⁻⁷

The first cases outside the African continent were only described in 2003, in the United States: an outbreak of 47 cases occurred after contact with infected pets, which acquired the virus from exotic animals imported from Ghana, without proper quarantine care.^{8,9} Isolated cases occurred in other countries, always associated with exposure to the African continent (for example, through travel).

As of May 2022, over 28,000 Monkeypox virus infections have been reported in over 93 countries. On July 23, 2022, the World Health Organization (WHO) declared a state of health emergency.¹⁰ The spread of the disease can be, in part, explained by the worldwide decline in immunity to the *Orthopoxvirus*, after 1980, with the eradication of smallpox in the world and the consequent suspension of vaccination in all countries.¹¹ Together, the neglect of the endemic disease on the African continent by world authorities allowed the continuity of the circulation of Monkeypox virus in human hosts, favoring the evolution of the pathogen and the emergence of newly adapted pathogens in humans.¹²

The clinical presentation of MKP in the 2022 outbreak is not similar to that of the already known smallpox, since prodromal symptoms (fever, myalgia, adenomegaly) may be absent in 40% to 60% of cases. The main feature of the current picture is the appearance of skin eruptions (single or multiple), which evolve sequentially from macules to papules, vesicles, pustules and crusts.¹³ In severe cases, the lesions may coalesce and ulcerate. The distribution is usually craniocaudal, with a centrifugal characteristic, affecting mainly the face, extremities and oral mucosa, in different stages of evolution. Lesions can start in the genital and perianal areas, not always spreading to other regions, which can be confused with other sexually transmitted infections.^{4,7}

Although epidemiological investigations are ongoing, the majority of cases reported in the recent outbreak occurred in men who have sex with men (MSM) through intimate skin-to-skin contact of sick individuals.¹⁰

Monkeypox infection can be confirmed by detection of the virus using the RT-PCR technique or isolation in viral culture from a sample of secretion from a lesion. There are no specific treatments available in Brazil, only clinical support is offered.¹⁴ The infected individual must remain in isolation until there is intact skin again, with resolution of the crusts. Most patients recover within four weeks, with a fatality rate of around 1–5%.¹⁵ More severe cases can occur due to complications such as pneumonitis, encephalitis, keratitis and secondary bacterial infections, especially in children under 8 years of age, pregnant and lactating women and immunosuppressed patients.

The first reported case of Monkeypox in a transplanted patient was on June 24, 2022, in Thailand.¹⁶ The patient had recently received a bone marrow transplant and presented a mild condition, with fever and rash, evolving with complete recovery and without any manifestations of severity. Through this MKP report in a recent solid organ transplant patient, we will seek to highlight the epidemiological profile and evolution of the virus in this specific population.

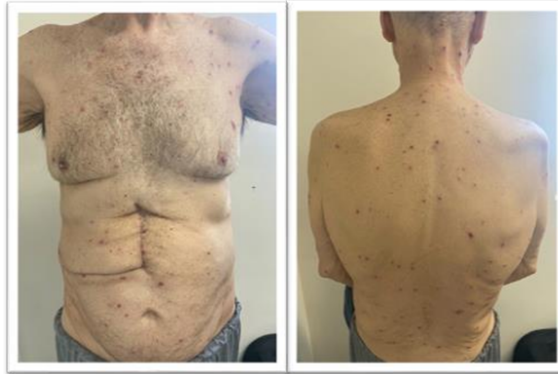CASE DESCRIPTION

J.C.R.P., male, 72 years old, with dyslipidemia, hypertension, type 2 diabetes, previously with liver cirrhosis secondary to metabolic syndrome, with persistent chronic anemia. Prioritized on liver transplant (LT) list due to refractory ascites with worsening renal function and need for paracentesis. He underwent LT in April 2022 with MELD 29. The donor was 24 years old, and his cause of death was traumatic brain injury. He had a good postoperative evolution, with a short stay in the ICU and, without complications, being discharged on the 17th postoperative day, when he recovered his renal function. At discharge, he was receiving immunosuppression with tacrolimus (with a serum level of 8.9 ng/ml); mycophenolate sodium 720 mg/day and prednisone 20 mg/day.

After a short hospitalization due to severe neutropenia (330 leukocytes), without associated infection, he remained in outpatient follow-up with biweekly follow-ups. In the second postoperative month, he required immunosuppression reduction due to esophageal moniliasis, being treated with fluconazole and oral nystatin for 21 days, and maintained in monotherapy with 14 mg / day of tacrolimus (serum level 6 ng / ml).

In the third postoperative month, he returned for consultation complaining of diffuse maculopapular lesions, painful on palpation, which started in the thoracic region and progressed to the lower limbs, abdomen, torso and cephalic region (see Fig. 1). He did not report fever and did not have lymph node enlargement on physical examination. He mentioned contact with unknown people two days before the appearance of the first lesion, but denied intimate contact with people who had MKP. The patient does not fit the epidemiological risk profile for MSM. He was hospitalized with isolation measures until further evaluation of the condition, and acyclovir was started on suspicion of chickenpox.

A swab was collected from the skin lesions, with a positive result for Monkeypox by RT-PCR. In view of this result, it was decided to suspend acyclovir and maintain it only with symptomatic drugs. Immunosuppression was adjusted, with tacrolimus reduction to 3mg/day, and prednisone dose increase to 20mg/day.

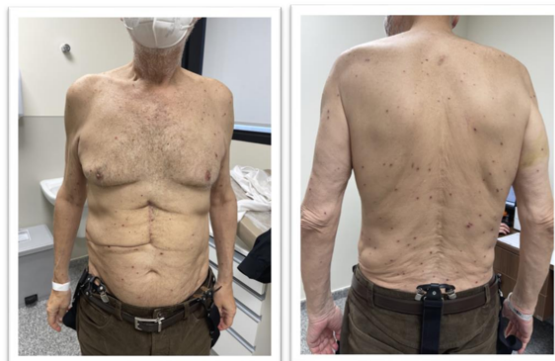

Source: Elaborated by the authors.

Figure 1. Multiple lesions on the torso and back at different stages of evolution (macules, papules, vesicles, pustules and crusts).

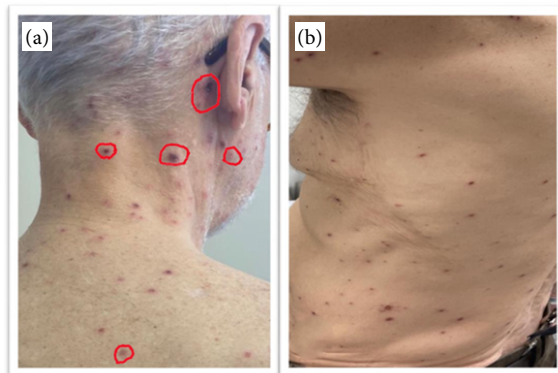
Despite the risk of complications due to immunosuppression, the patient evolved well, without significant laboratory changes: hemoglobin 9.1 g/dL, leukocytes 3170/mm³, platelets 98,600/mm³, C-Reactive Protein (CRP) 0.39 mg/dL, Oxalacetic Transaminase (GO-T) 24 U/L, Pyruvic Transaminase (GP-T) 118 U/L, Gamma-Glutamyl Transferase (GGT) 87 U/L Alkaline Phosphatase (ALP) 139 U/L, serum tacrolimus dosage at admission of 2 ng/mL. He was discharged after four days, with no complaints and with an indication to remain in isolation until completing thirty days after the appearance of the first lesion.

The patient was reassessed ten days after discharge, with the lesions already healing to crusts (as shown in Fig. 2), asymptomatic, with normal liver function tests, using tacrolimus 4 mg/day (serum level 2.9 ng/ml), restarting sodium mycophenolate 720 mg/day and reducing prednisone to 5 mg/day and suspending schedule at the end of the third month of transplantation.



Source: Elaborated by the authors.

Figure 2. Aspect of the lesions on the torso and back two weeks later.



Source: Elaborated by the authors.

Figure 1. Comparative showing macules, papules, vesicles and pustules (a) and two weeks later, showing the evolution of all lesions to crusts (b).

DISCUSSION

Infectious conditions are frequent complications in transplant patients, and viral infections usually appear one month after the surgical procedure, with a peak between 3–6 months (period of greatest immunosuppression).¹⁷ The most prevalent opportunistic viruses are: cytomegalovirus, herpes virus, varicella-zoster virus and Epstein-Barr virus. In addition, we also observed an increase in the prevalence of community viral infections, such as those caused by Influenza viruses, Norovirus and, more recently, by the new Coronavirus.¹⁸

Given this particularity, we cautiously observe the emergence of the new Monkeypox virus, due to the possible risks associated with immunosuppressed patients. The data available so far, however, do not infer greater severity in these patients, although the literature is still scarce.

The Monkeypox epidemic of 2022 differs from previous outbreaks described mainly due to a less severe clinical picture, with a very low lethality in the affected population, especially in non-endemic regions.¹⁹ Based on this data, it is still too early to determine risk groups for a more severe involvement. In previous outbreaks, immunocompromised patients, along with children and pregnant women, were part of the risk group.²⁰

As of August 6, 2022, we found no case reports of Monkeypox in solid organ transplantation.²¹ This report has two interesting aspects: the first concerns the lack of epidemiological antecedents for Monkeypox. Current knowledge brings intimate skin-to-skin contact as the main route of transmission, which was not described by our patient. The literature questions the possibility and importance of respiratory transmission,⁸ which can be particularly significant for immunosuppressed patients, becoming a possibility for this patient.

This report also warns that, even in the absence of epidemiological risk factors, Monkeypox should always be investigated when there are skin and mucosal lesions with characteristics suggestive of this infection. Another highlight of this report is that the evolution of the clinical picture, despite a significant number of skin lesions and the lack of specific antiviral medication, was without severity and without complications, only with clinical support and adjustment of the immunosuppression already used by the patient.

Some questions still remain in relation to Monkeypox in the scenario of solid organ transplants:

- What is the degree of clinical accuracy for diagnosing this infection: are the medical team and patients properly oriented towards the clinical suspicion of Monkeypox?
- What will be the impact of this infection in relation to lethality and mortality?
- Will Monkeypox-specific antivirals be indicated for all solid organ transplants or only for patients with signs of severity?
- Is there a need for adjustments in immunosuppression?

CONCLUSION

We still do not have objective answers or definitions about the epidemiology and evolution of Monkeypox in solid organ transplant patients. In the meantime, we consider it important to alert the transplant community about the need for a high degree of diagnostic suspicion in the face of typical lesions, and adequate guidance to transplant patients regarding risk exposures (intimate contact, closed environments, contact with fomites).

CONFLICT OF INTEREST

None.

AUTHOR'S CONTRIBUTION

Substantive scientific and intellectual contributions to the study: Genzini T, Almeida TN, Rodrigues MG, Marzinotto MAN, Stucchi RSB; **Conception and design:** Genzini T, Almeida TN, Stucchi RSB; **Data analysis and interpretation:** Genzini T, Almeida TN, Rodrigues MG, Figueiredo SR, Marzinotto MAN, Fonseca LEP, Stucchi RSB, Rodriguez TN, Santos RG, Perosa M; **Article writing:** Genzini T, Almeida TN, Rodrigues MG, Marzinotto MAN, Stucchi RSB; **Critical revision:** Genzini T, Almeida TN, Rodrigues MG, Figueiredo SR, Marzinotto MAN, Fonseca LEP, Stucchi RSB, Rodriguez TN, Santos RG, Perosa M; **Final Approval:** Genzini T, Almeida TN, Rodrigues MG, Figueiredo SR, Marzinotto MAN, Fonseca LEP, Stucchi RSB, Rodriguez TN, Santos RG, Perosa M.

DATA AVAILABILITY STATEMENT

All datasets were generated or analyzed in the current study.

FUNDING

Not applicable.

ACKNOWLEDGEMENT

To the multidisciplinary team that takes care of the pre, intra and postoperative care of patients with liver disease undergoing liver transplants at our institution.

REFERENCES

1. Khodakevich L, Szczeniowski M, Disu N-m, Jezek Z, Marennikova S, Nakano J, et al. Monkeypox in relation to ecological features surrounding human settlements in the Bumba area, Zaire. *Trop Geogr Med.* 1987;39(1):56-63.
2. Halani S, Mishra S, Bogoch II. The monkeypox virus. *CMAJ.* 2022;194(24):E844. <https://doi.org/10.1503/cmaj.220795>
3. Reynolds MG, McCollum AM, Nguete B, Lusgima RS, Petersen WB. Improving the Care and Treatment of Monkeypox Patients in Low- Resource Settings: Applying Evidence from Contemporary Biomedical and Smallpox Biodefense Research. *Viruses.* 2017;9(12):380. <https://doi.org/10.3390/v9120380>
4. Thornhill JP, Barkati S, Walmsley S, Rockstroh J, Antinori A, Harrison LB, et al. Monkeypox Virus Infection in Humans across 16 Countries – April-June 2022. *N Engl J Med.* 2022;387(8):679-91. <https://doi.org/10.1056/NEJMoa2207323>
5. Centers for Disease Control and Prevention [CDC]. Human monkeypox – Kasai Oriental, Democratic Republic of Congo, February 1996-October 1997. *MMWR Morb Mortal Wkly Rep.* 1997;46(49):1168-71.
6. Durski KN, McCollum AM, Nakazawa Y, Petersen BW, Reynolds MG, Briand S, et al. Emergence of monkeypox — West and Central Africa, 1970–2017. *Morbidity and Mortality Weekly Report;* 2018;67(10):306-10. <https://doi.org/10.15585/mmwr.mm6710a5>
7. Bunge EM, Hoet B, Chen L, Lienert F, Weidenthaler H, Baer LR, et al. The changing epidemiology of human monkeypox—A potential threat? A systematic review. *PLoS Negl Trop Dis.* 2022;16(2):e0010141. <https://doi.org/10.1371/journal.pntd.0010141>
8. Centers for Disease Control and Prevention [CDC]. Monkeypox Signs and Symptoms. Department of Health & Human Services [Internet]; 2022. [acesso em 2022 jul 27]. Disponível em: <https://www.cdc.gov/poxvirus/monkeypox/index.html>
9. Huhn GD, Bauer AM, Yorita K, Graham MB, Sejvar J, Likos A, et al. Clinical characteristics of human monkeypox, and risk factors for severe disease. *Clin Infect Dis.* 2005;41(12):1742-51. <https://doi.org/10.1086/498115>
10. World Health Organization [WHO]. Multi-country monkeypox outbreak: situation update [Internet]; 2022. [acesso em 2022 jul 27]. Disponível em: <https://www.who.int/emergencies/disease-outbreak-news/item/2022-DON396>
11. Monkeypox: background information. UK Health Security Agency – GOV.UK [Internet]; 2022. [acesso em 2022 ago 1]. Disponível em: <https://www.gov.uk/guidance/monkeypox#transmission>
12. Grant R, Nguyen L-BL, Breban R. Modelling human-to-human transmission of monkeypox. *Bull World Health Organ.* 2020;98(9):638-40. <https://doi.org/10.2471/BLT.19.242347>
13. Agência Nacional de Vigilância Sanitária [ANVISA]. Nota técnica GVIMS/GGTES/ANVISA nº 03/2022 orientações para prevenção e controle da Monkeypox nos serviços de saúde. Brasília: GVIMS/GGTES/ANVISA; 2022. [acesso em 2022 maio 31]. Disponível em: <https://www.gov.br/anvisa/pt-br/centraisdeconteudo/publicacoes/servicosdesaude/notas-tecnicas/nota-tecnica-gvims-ggtes-anvisa-no-03-2022-orientacoes-para-prevencao-e-controle-da-monkeypox-nos-servicos-de-saude>
14. Moore MJ, Rathish B, Zahra F. Monkeypox. StatPearls Publishing [Internet]; 2022. [acesso em 2022 jul 27]. Disponível em: https://www.ncbi.nlm.nih.gov/books/NBK574519/#_NBK574519_pubdet
15. Sklenovská N, Van Ranst M. Emergence of Monkeypox as the Most Important Orthopoxvirus Infection in Humans. *Front Public Health.* 2018;6:241. <https://doi.org/10.3389/fpubh.2018.00241>
16. Mungmunpantipantip R, Wiwanitkit V. Monkey pox and transplant recipient: Current issue in transplantation medicine. *Transpl Infect Dis.* 2022;24(6):e13884. <https://doi.org/10.1111/tid.13884>
17. Mohanraj BS, Rangnekar AS, Timpone Junior JG. Infections in Liver Transplantation. In: Safdar A, editor. *Principles and Practice of Transplant Infectious Diseases.* New York: Springer; 2019. p. 41-72. https://doi.org/10.1007/978-1-4939-9034-4_3

18. Jothimani D, Venugopal R, Vij M, Rela M. Post liver transplant recurrent and de novo viral infections. *Best Pract Res Clin Gastroenterol.* 2020;46-47:101689. <https://doi.org/10.1016/j.bpg.2020.101689>
19. Kmiec D, Kirchhoff F. Monkeypox: A New Threat? *Int J Mol Sci.* 2022;23(14):7866. <https://doi.org/10.3390/ijms23147866>
20. Luo Q, Han J. Preparedness for a monkeypox outbreak. *Infectious Medicine.* 2022;1(2):124-4. <https://doi.org/10.1016/j.imj.2022.07.001>
21. American Society of Transplantation (AST). Monkeypox FAQs for Transplant Community. Released: August 4, 2022 [Internet]; 2022. [acesso em 2022 ago 4]. Disponível em: <https://www.myast>